



COVID-19 pandemic and cardiac imaging: EACVI recommendations on precautions, indications, prioritization, and protection for patients and healthcare personnel

Helge Skulstad^{1,2}, Bernard Cosyns ³, Bogdan A. Popescu⁴, Maurizio Galderisi⁵, Giovanni Di Salvo⁶, Erwan Donal⁷, Steffen Petersen^{8,9}, Alessia Gimelli¹⁰, Kristina H. Haugaa^{1,2}, Denisa Muraru¹¹, Ana G. Almeida¹², Jeanette Schulz-Menger^{13,14,15}, Marc R. Dweck¹⁶, Gianluca Pontone¹⁷, Leyla Elif Sade¹⁸, Bernhard Gerber¹⁹, Pal Maurovich-Horvat²⁰, Tara Bharucha²¹, Matteo Cameli²², Julien Magne^{23,24}, Mark Westwood⁹, Gerald Maurer²⁵, and Thor Edvardsen ^{1,2*}

¹Department of Cardiology, Oslo University Hospital, Rikshospitalet, Oslo, Norway; ²Faculty of Medicine, University of Oslo, Oslo, Norway; ³Centrum voor Hart en Vaatziekten (CHVZ), Universitair Ziekenhuis Brussel, Vrij Universiteit van Brussel, Brussels, Belgium; ⁴Department of Cardiology, University of Medicine and Pharmacy 'Carol Davila' Eurocolab, Emergency Institute for Cardiovascular Diseases 'Prof. Dr. C. C. Iliescu', Bucharest, Romania; ⁵Department of Advanced Biomedical Sciences, Federico II University Hospital, Naples, Italy; ⁶University Hospital Padua, Paediatric Cardiology, Padua, Italy; ⁷University of Rennes, CHU Rennes, Inserm, LTSI-UMR 1099, Rennes, France; ⁸William Harvey Research Institute, NIHR Barts Biomedical Research Centre, Queen Mary University of London, London, UK; ⁹Barts Heart Centre, St Bartholomew's Hospital, Barts Health NHS Trust, London, UK; ¹⁰Fondazione Toscana G. Monasterio, Pisa, Italy; ¹¹Department of Medicine and Surgery, University of Milano-Bicocca, Milan, Italy; ¹²Cardiology, University Hospital Santa Maria /CHLN, CCUL, Faculty of Medicine of Lisbon University, Lisbon, Portugal; ¹³Charité Medical Faculty of the Humboldt University Berlin, ECRC, Berlin, Germany; ¹⁴DZHK, Partner site, Berlin, Germany; ¹⁵Helios Clinics Berlin-Buch, Cardiology, Berlin, Germany; ¹⁶Centre for Cardiovascular Science, University of Edinburgh, UK; ¹⁷Department of Cardiovascular Imaging, Centro Cardiologico Monzino IRCCS, Milan, Italy; ¹⁸Department of Cardiology, University of Baskent, Ankara, Turkey; ¹⁹Division of Cardiology, Department of Cardiovascular Diseases, Cliniques Universitaires St. Luc, Pôle de Recherche Cardiovasculaire, Institut de Recherche Expérimentale et Clinique, Université Catholique de Louvain, Brussels, Belgium; ²⁰Medical Imaging Centre, Semmelweis University, Budapest, Hungary; ²¹Department of Congenital Cardiology, University Hospital Southampton NHS Foundation Trust, Southampton, UK; ²²Department of Medical Biotechnologies, Division of Cardiology, University of Siena, Siena, Italy; ²³CHU Limoges, Hôpital Dupuytren, Service Cardiologie, Limoges, France; ²⁴INSERM U1094, Univ. Limoges, CHU Limoges, IRD, U1094, GEIST, 2, Limoges, France; and ²⁵Division of Cardiology, Department of Internal Medicine II, Medical University of Vienna, Vienna, Austria

Received 25 March 2020; editorial decision 25 March 2020; accepted 25 March 2020

Introduction

The coronavirus disease 2019 (COVID-19) pandemic has created new and unpredictable challenges for modern medicine and healthcare systems. Preliminary reports have demonstrated that older age, previous cardiovascular disease, diabetes, and hypertension are risk factors for increased mortality.¹ Data on the cardiac affinity of the virus and its potential to harm the cardiovascular system and the mechanisms by which this occurs are sparse.^{2,3} A systemic infection generally increases demand on the heart, and can exacerbate underlying cardiac conditions. When the lungs are heavily involved, as seen in COVID-19 patients, this may have a major impact on cardiac function, particularly that of the right ventricle. Finally, COVID-19 may have direct effects on the heart, as may some drugs being used in its treatment.

The severe acute respiratory syndrome coronavirus-2 (SARS-CoV-2) is responsible for COVID-19 and is transmitted by droplets from person to person.⁴ Echocardiographers in particular, and cardiac imagers more generally, are in close contact with patients and therefore likely to have a high risk of being infected. To decrease the risk of patient to patient, patient to imager, and imager to patient contamination, the indication for any cardiac imaging test should be carefully considered, and only those tests considered essential to patient care performed.

Cardiologists and cardiology departments are heavily affected by this rapidly changing situation.⁵ The COVID-19 pandemic also increases the burden on cardiac imaging services generally. However, given its wide availability and key role as a bedside test, echocardiography is the most affected cardiac imaging modality. Common challenges faced by all cardiac imaging modalities during the pandemic

* Corresponding author. Department of Cardiology, Oslo University Hospital, Rikshospitalet, Sognsvannsveien 20, 0372 Oslo, Norway/PO Box 4950 Nydalen, NO-0424 Oslo, Norway. Tel: +47 2 3071176, Email: thor.edvardsen@medisin.uio.no

Published on behalf of the European Society of Cardiology. All rights reserved. © The Author(s) 2020. For permissions, please email: journals.permissions@oup.com.

Key point 3

Advice for cardiac imaging

- Echocardiography should not routinely be performed in patients with COVID-19 disease
- A range of different cardiovascular manifestations can be found in COVID-19 which may require cardiac imaging, including a bedside echocardiographic study
- A focused cardiac ultrasound study (FoCUS) is recommended to reduce the duration of exposure
- The risk of contamination of equipment and personnel is very high during TOE—consider repeat TTE, CT scan, or CMR as alternatives
- Chest CT is frequently used to confirm COVID-19 pneumonia and might provide possible synergies and opportunities of cardiac imaging
- Coronary CT angiography can exclude or confirm an acute coronary syndrome in COVID-19 pneumonia where elevated troponins are common
- LV function can be assessed by LV angiogram in patients with acute coronary syndromes during the invasive revascularization procedure
- Positive troponins and myocardial dysfunction or severe arrhythmia suggestive of Tako-tsubo or myocarditis may be an indication for acute CMR if of vital importance for treatment, and patient can be safely transferred for imaging
- Indications for foetal echocardiography remain the same as outside the COVID-19 pandemic

Echocardiography should not routinely be performed in patients with typical signs of COVID-19 disease. Indeed, it should be restricted to those patients in whom it is likely to result in a change in management. Nevertheless, many COVID-19 patients will develop a range of different cardiovascular manifestations which will require a bedside echocardiographic study.⁷ Moreover, there are reasons to believe that the need for echocardiography might expand further as we understand more about COVID-19, with early reports indicating that patients with established cardiovascular disease and cardiovascular risk factors have worse prognosis than others, and are more likely to be admitted to hospital and need respiratory support.¹

Dyspnoea is a typical finding in patients with cardiac disease, and echocardiography may be indicated in the diagnostic work-up, particularly in patients with subacute onset of dyspnoea, oedema, or cardiac murmurs and elevated cardiac biomarkers. Conversely, a normal pro-BNP test can frequently be used to exclude the need for an echocardiogram in patients with dyspnoea or oedema.

In the ICU, echocardiography has sometimes been used to routinely monitor the progress of certain patients.⁷ This should not be routinely performed in the COVID-19 pandemic. Instead, echocardiography should be restricted to patients with cardiovascular instability or signs of right ventricular dysfunction or pulmonary hypertension. Lung ultrasound to detect COVID-19 pneumonia is also useful.⁸ Thickening of the pleurae, the appearance of B-lines, and lung consolidation indicate pneumonia, with pleural effusions rarely reported. Due to its bedside availability, scanning of the lungs by ultrasound can be performed as a quick diagnostic tool.

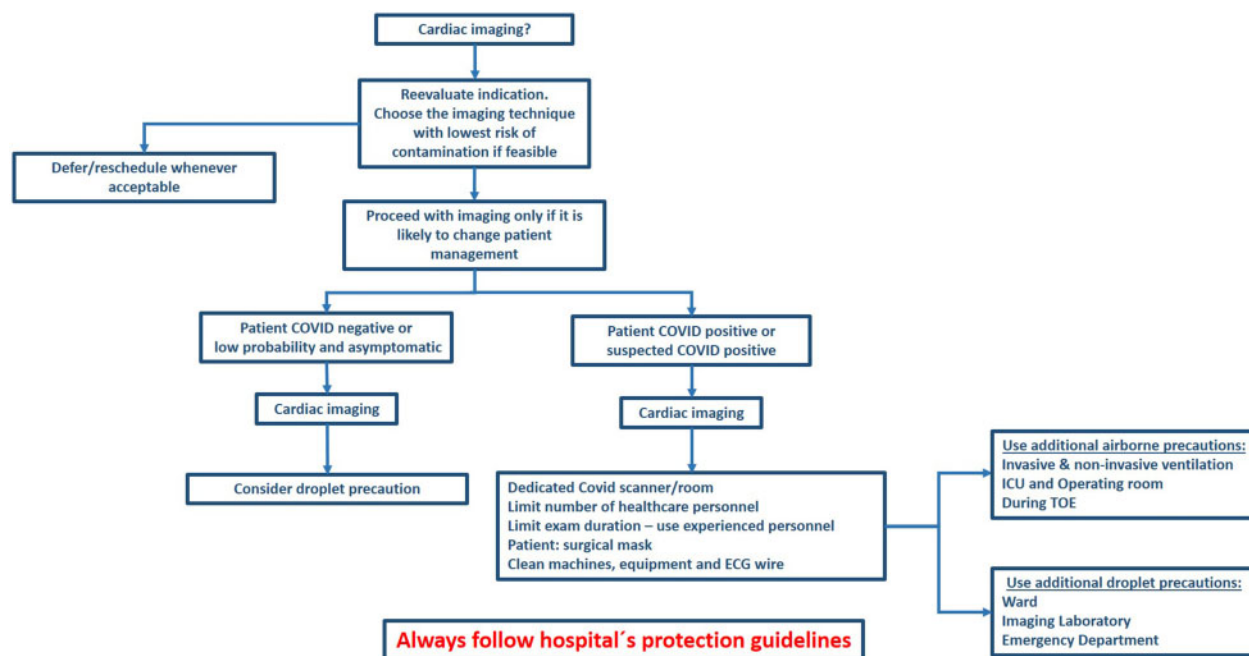


Figure 1 Suggested considerations and precautions before and during cardiac imaging.

patient, and the minimum number of healthcare professionals should attend scanning and counselling.

Indication for other imaging methods

Given the acute nature of the disease, and restrictions of hospital facilities for chronic patients, there are probably few defined indications for coronary CT angiography, CMR, or nuclear cardiology in patients with COVID-19 infection during the acute phase.

Similar to the situation for echocardiography, patients scheduled for CMR, CT, and nuclear cardiology, with non-severe symptoms or not eligible for invasive or surgical treatment, should be postponed. Routine follow-up scans should be re-scheduled. A possible indication for CMR is the suspicion of COVID-19 myocarditis, but the clinical implication of detecting myocarditis in these patients is not determined. We suggest that positive troponins and myocardial dysfunction or severe arrhythmia not explained by other methods may be an indication for acute CMR if of crucial importance for the treatment and the patient is stable enough to be scanned.

Cleaning, disinfection, and protection in patients with suspected or confirmed COVID-19

Equipment

All equipment used in close contact with patients has the potential to carry droplets containing the virus. This includes ECG leads which should therefore be avoided when performing echocardiographic studies in COVID-19 patients.

Moderately warm water and a mild detergent constitute the basis of equipment cleaning in all cardiac imaging machines, including the echocardiographic probe. An ordinary water-soluble disinfectant should also be added, but not on the membrane. A non-alcoholic

disinfectant should be used on the echocardiographic probe (please confirm with recommendations for each vendor). Dedicated wipes may also be used in this process.

Protecting the echocardiographic machines with custom-made covers may be possible if available, but, if not, other protective equipment can be fashioned using local entrepreneurs and ingenuity. It is, however, important not to cover the screen in a way that reduces the view for the echocardiographer. This may reduce the quality of the study and increase scan duration. Similarly, the keyboard should be fully operative during the investigation. To facilitate the cleaning of the scanner, all additional 3-D and single-Doppler probes should be removed before the scanning starts, if they are not needed for proper diagnosis. ECG leads should also be removed, although this may make the recordings of loops more difficult and potentially more time consuming. In high-volume centres, one can consider dedicating separate scanners to be used exclusively for COVID-19-positive patients, that remain within designated COVID-19 areas. No additional disinfection procedure is necessary for a TOE probe as every location should have proper routines for cleaning and disinfection of these probes. A protective coat on the TOE probe might also be considered.

The positioning of the patient vs. the echocardiographer and the scanner may be of importance. Patients placed in the left lateral position with the scanner positioned on the right side of the bench will result in the longest possible distance between the faces of the patient and the echocardiographer. The contamination of the scanner by airborne droplets from the patient will also probably be minimized. However, the preferred patient position is different among echocardiographers, and these recommendations should not be a hindrance to performing high-quality fast echocardiograms. A surgical mask on the patient will also reduce contamination by air droplets.

Facilities

The echocardiographic study will usually be performed in the ICU or in emergency rooms in critically ill patients. Less critical patients are usually examined in their ward rooms. Dedicated room(s) may be prepared in the echocardiographic lab, where unnecessary equipment can be removed to make the cleaning of the room as easy as possible. However, there is less risk of virus spread if the

Table 1 Recommendations during TTE and foetal echo

Risk of contamination	Handwashing	Surgical mask and gloves	Protective clothing, eye protection	Head cap	Study completeness	Equipment protection
Lower risk	Obligatory	Preferable	Probably not	No	Full	None
Moderate risk	Obligatory	Obligatory	Preferable	No	Preferably full/depending on severity of the cardiac pathology	Intermediate/protection of probe, leads, and other parts near the patient
Severe risk/ confirmed COVID-19	Obligatory	Advanced mask: FFP2/FFP3/N95/N99	Obligatory	Obligatory	Problem focused, adjusted for clinical importance of the cardiac pathology	Full cover/dedicated scanners

Lower risk, patients with no symptoms, no increased risk behaviour, a recent negative virus test, or in areas with low risk of COVID-19. Moderate risk, patients with non-specific/unclear symptoms or patients without symptoms in an area with moderate or high risk of COVID-19. Severe risk, patients with typical symptoms or confirmed COVID-19. FFP2, Filtering Facepiece Particulate class 2 (FFP2 corresponds to US N95, FFP3 corresponds to US N99).

References

1. Wu Z, McGoogan JM. Characteristics of and important lessons from the coronavirus disease 2019 (COVID-19) outbreak in China: summary of a report of 72314 cases from the Chinese Center for Disease Control and Prevention. *JAMA* 2020;doi:10.1001/jama.2020.2648.
2. Zheng Y-Y, Ma Y-T, Zhang J-Y, Xie X. COVID-19 and the cardiovascular system. *Nat Rev Cardiol* 2020;doi:10.1038/s41569-020-0360-5.
3. Xiong T-Y, Redwood S, Prendergast B, Chen M. Coronaviruses and the cardiovascular system: acute and long-term implications. *Eur Heart J* 2020;doi:10.1093/eurheartj/ehaa231.
4. Chan JF-W, Yuan S, Kok K-H, To KK-W, Chu H, Yang J, Xing F, Liu J, Yip CC-Y, Poon RW-S, Tsoi H-W, Lo SK-F, Chan K-H, Poon VK-M, Chan W-M, Ip JD, Cai J-P, Cheng VC-C, Chen H, Hui CK-M, Yuen K-Y. A familial cluster of pneumonia associated with the 2019 novel coronavirus indicating person-to-person transmission: a study of a family cluster. *Lancet* 2020;**395**:514–523.
5. Elkind MS, Harrington RA, Benjamin EJ. Role of the American Heart Association in the global COVID-19 pandemic. *Circulation* 2020;doi:10.1161/CIRCULATION.AHA.120.046749.
6. Knuuti J, Wijns W, Saraste A, Capodanno D, Barbato E, Funck-Brentano C, Prescott E, Storey RF, Deaton C, Cuisset T, Agewall S, Dickstein K, Edvardsen T, Escaned J, Gersh BJ, Svitil P, Gilard M, Hasdai D, Hatala R, Mahfoud F, Masip J, Muneretto C, Valgimigli M, Achenbach S, Bax JJ, ESC Scientific Document Group. 2019 ESC Guidelines for the diagnosis and management of chronic coronary syndromes. *Eur Heart J* 2020;**41**:407–477.
7. Lancellotti P, Price S, Edvardsen T, Cosyns B, Neskovic AN, Dulgheru R, Flachskampf FA, Hassager C, Pasquet A, Gargani L, Galderisi M, Cardim N, Haugaa KH, Ancion A, Zamorano J-L, Donal E, Bueno H, Habib G. The use of echocardiography in acute cardiovascular care: recommendations of the European Association of Cardiovascular Imaging and the Acute Cardiovascular Care Association. *Eur Heart J Cardiovasc Imaging* 2015;**16**:119–146.
8. Peng Q-Y, Wang X-T, Zhang L-N. Chinese Critical Care Ultrasound Study Group (CCUSG). Findings of lung ultrasonography of novel corona virus pneumonia during the 2019–2020 epidemic. *Intensive Care Med* 2020;doi:10.1007/s00134-020-05996-6
9. Neskovic AN, Skinner H, Price S, Via G, De Hert S, Stankovic I, Galderisi M, Donal E, Muraru D, Sloth E, Gargani L, Cardim N, Stefanidis A, Cameli M, Habib G, Cosyns B, Lancellotti P, Edvardsen T, Popescu BA, Reviewers: This document was reviewed by members of the 2016–2018 EACVI Scientific Documents Committee. Focus cardiac ultrasound core curriculum and core syllabus of the European Association of Cardiovascular Imaging. *Eur Heart J Cardiovasc Imaging* 2018;**19**:475–481.
10. Cardim N, Dalen H, Voigt J-U, Ionescu A, Price S, Neskovic AN, Edvardsen T, Galderisi M, Sicari R, Donal E, Stefanidis A, Delgado V, Zamorano J, Popescu BA. The use of handheld ultrasound devices: a position statement of the European Association of Cardiovascular Imaging (2018 update). *Eur Heart J Cardiovasc Imaging* 2019;**20**:245–252.
11. Habib G, Lancellotti P, Antunes MJ, Bongiorni MG, Casalta J-P, Del Zotti F, Dulgheru R, El Khoury G, Erba PA, Jung B, Miro JM, Mulder BJ, Plonska-Gosciniak E, Price S, Roos-Hesselink J, Snygg-Martin U, Thuny F, Tornos Mas P, Vilacosta I, Zamorano JL, ESC Scientific Document Group. 2015 ESC Guidelines for the management of infective endocarditis: The Task Force for the Management of Infective Endocarditis of the European Society of Cardiology (ESC). Endorsed by: European Association for Cardio-Thoracic Surgery (EACTS), the European Association of Nuclear Medicine (EANM). *Eur Heart J* 2015;**36**:3075–3128.
12. Neglia D, Liga R, Caselli C, Carpeggiani C, Lorenzoni V, Sicari R, Lombardi M, Gaemperli O, Kaufmann PA, Scholte AJHA, Underwood SR, Knuuti J, EVINCI Study Investigators. Anatomical and functional coronary imaging to predict long-term outcome in patients with suspected coronary artery disease: the EVINCI-outcome study. *Eur Heart J Cardiovasc Imaging* 2019;doi:10.1093/ehjci/jez248
13. Donofrio MT, Moon-Grady AJ, Hornberger LK, Copel JA, Sklansky MS, Abuhamad A, Cuneo BF, Huhta JC, Jonas RA, Krishnan A, Lacey S, Lee W, Michelfelder EC, Rempel GR, Silverman NH, Spray TL, Strasburger JF, Tworetzky W, Rychik J, American Heart Association Adults With Congenital Heart Disease Joint Committee of the Council on Cardiovascular Disease in the Young and Council on Clinical Cardiology, Council on Cardiovascular Surgery and Anesthesia, and Council on Cardiovascular and Stroke Nursing. Diagnosis and treatment of fetal cardiac disease: a scientific statement from the American Heart Association. *Circulation* 2014;**129**:2183–2242.